Arab Gulf J. scient. Res. **2** (1), pp. 221-238 (1984)

The Postembryonic Development of the Chondrocranium in the Nile Fish *Sarotherodon galilaeus* Linnaeus (Teleostei : Cichlidae)

II. The Postbuccal Stages

Momtaz H. Ismail

Department of Zoology, Faculty of Science, Zagazig University, Zagazig, Egypt.

ABSTRACT.The development of the chondrocranium of two postbuccal stages of *Sarotherodon galilaeus (= Tilapia galilaea)* (9 mm and 12 mm total length; 11 and 14 days old after fertilization, respectively) is described and compared with that of other bony fishes.

In the 9 mm stage, absorption of cartilage is observed at the level of the fenestra hypophysea and becomes more pronounced in the 12 mm stage, early as compared with that in other bony fishes. The disparity is probably due to differences in environmental conditions.

The neurocranial pharyngobranchiad apophysis, characteristic of the cichlid neurocranium, is developed from stage 9 mm onwards as a slight ventral projection of the neurocranial base in the otic region.

The parachordal plates are connected posteriorly with each other by means of an epichordal commissure.

The taenia tecti medialis originates as a posterior median extension of the epiphyseal cartilaginous bar.

An interorbital septum is present. It consists anteriorly of cartilage and posteriorly of connective tissue membrane.

A single, median, independent rostral cartilage is present dorsal to the ethmoid plate.

The palatoquadrate cartilage articulates anteriorly with the neurocranium by means of an ethmopalatine articulation; a rostropalatine articulation, however, is absent.

This study is the second in a series dealing with the development of the cranium of the biparental mouth-breeding cichlid fish, *Sarotherodon galilaeus**. The first of the series deals with the postembryonic development of two developmental buccal stages (5 mm and 7 mm in length) (Ismail and Elshabka 1982).

---

* A recent publication by Trewavas (1982) had revised the nomenclature of *Tilapia* species. *Tilapia galilaea* (L.) is now substituted by *Sarotherodon galilaeus* (L.).

In the present study, the morphology of the chondrocranium of two postbuccal stages is reviewed and compared with that of other bony fishes.

Material and Methods

From a population of adult males and females of *S. galilaeus*, cultivated in the laboratory in an aquarium (26-30° C) aerated by an electric air pump, developmental stages were selected and fixed in 4% formalin and then transferred to aqueous Bouin's solution.

For the present study, two developmental postbuccal stages, at 9 mm and 12 mm total length, 11 and 14 days old after fertilization, respectively, were used. Samples were collected at intervals after release from development within the buccal cavity where broods are protected by parents in *S. galilaeus*.

Following decalcification in EDTA solution, serial transverse, sagittal and frontal sections were cut at 7-10 μ thickness, and stained by haematoxylin-eosin and Mallory's triple stain.

Graphical reconstructions conformed with the Verraes (1974b) technique.

Observations

Stage I (9 mm total length, Fig. 1, 2 and 3)

This stage exhibits both an over-all growth of chondrocranial cartilage and pronounced absorption of it. The cartilaginous neurocranium is relatively as well as actually both longer and wider than in the buccal stage at the 7 mm length (Ismail and Elshabka 1982).

The continuity of the cartilaginous neurocranium between the trabeculae cranii and the parachordal plates (Ismail and Elshabka 1982), as observed in the 7 mm stage at the level of the fenestra hypophysea is lost in this stage due to absorption of cartilage. Consequently, the trabecula communis loses its connection with the parachordal plates (Fig. 1B and 2A). Anteriorly, the trabecula communis appears as a posteriorly directed, pointed process of the ethmoid plate. Posterior to it, a small median cartilaginous island represents the remnant of the absorption process of the trabecula communis (Fig. 1A and 2A).

The parachordal plates, that form the principal part of the cartilaginous neurocranial base, are united with each other above the anteriormost part of the notochord by a cartilaginous pro-otic bridge (Fig. 1B). Farther forward the parachordals of the two sides separate from each other, thus enclosing a wide space representing the fenestra hypophysea. Anteriorly, the fenestra hypophysea is open due to absorption of cartilage. Arising from the anteromedial border of the parachordal plate on each side is a small process representing the residual part of the posterior limb of the trabecula crani (Fig. 1B and 2A).

Posterior to the pro-otic bridge, an elongate interparachordal fenestra (Norman 1926) is entirely occupied by the notochord (Fig. 1B). This fenestra is bordered anteriorly by the posterior margin of the cartilaginous pro-otic bridge, laterally by the medial borders of the parachordal and occipital plates, and posteriorly by an epichordal cartilaginous commissure (Fig. 2A). A similar commissure has been described in *Anguilla vulgaris* (Norman 1926), *Mastcembelus armatus* (Bhargava 1958) and *Haplochromis elegans* (Ismail 1979).

The anterior tip of the notochord, which projects slightly into the fenestra hypophysea in the 7 mm stage (Ismail and Elshabka 1982), has regressed farther caudally, nearly to the middle of the pro-otic bridge. Such caudal regression of the notochord may be due to a rapid growth of the surrounding parts of the cartilaginous neurocranium, to a slow growth rate of the notochord as compared with that of the surrounding cartilages or to a resorption of the notochord itself.

In lateral view, and at about the level of the foramen glossopharyngeum, the cartilaginous neurocranial base shows a shallow ventral convexity, representing a part of the future neurocranial pharyngobranchiad apophysis (Fig. 1A), characteristic of the cichlid neurocranium (Fryer and Iles 1972, and Barel *et al.* 1976).

The trabecula communis is continued forward as a broad massive ethmoid plate (Fig. 1B and 2A) and bears a shallow ventral median groove (Fig. 3A). The ethmoid plate projects slightly forward into a narrow rostrum, and and internasal septum appears, from its centre, as a median process projecting dorsad (Fig. 3B). The posterolateral sides of the ethmoid plate are raised upward to form a lamina orbitonasalis on each side (Fig. 1A and 3B), anteriorly extending slightly lateral to the olfactory sac (Fig. 3A). In dorsal and ventral views, the lamina orbitonasalis appears as a small process projecting laterad from the ethmoid plate on each side (Fig. 1B and 2A). In lateral view, however, it appears as a vertical cartilaginous strand continuous dorsally with the taenia marginalis anterior and ventrally with the ethmoid plate (Fig. 1A and 3B).

Dorsal to the anterior part of the ethmoid plate and in front of the nasal septum, is an independent element, the rostral cartilage. In lateral view, it appears roughly triangular in shape, broad anteriorly and narrow posteriorly (Fig. 1A).

The orbital cartilages or taeniae marginales are well developed and extend from the ethmoid region anteriorly to the auditory capsules posteriorly (Fig. 1A, 1B and 2A). The two orbital cartilages are connected together by an epiphyseal cartilaginous bar dividing the taenia marginalis on each side into an anterior and a posterior part. Anterior to the epiphyseal cartilaginous bar, the two orbital cartilages run nearly parallel to each other and expand in the ethmoid region to form the sphenoseptal commissures (Fig. 1B). Posterior to the epiphyseal cartilaginous bar the orbital cartilages are much wider and diverge laterally to join the auditory capsules. Dorsally, the epiphyseal cartilaginous bar divides the neurocranial roof into two fontanelles: an anterior, smaller fontanella praepinealis and a posterior, larger fontanella postpinealis (Fig. 1B).

The interorbital septum separating the eyes is well developed and consists anteriorly of cartilage (Fig. 3C). Posteriorly, however, it is membranous and is attached dorsally to the membranous wall of the brain and ventrally to the median ridge of the trabecula communis (Fig. 3D).

The lateral commissure, which is developed in the 7 mm stage as a continuous cartilaginous plate extending between the anteromedial side of the auditory capsule and the lateral edge of the parachordal plate (Ismail and Elshabka 1982), is now lost due to cartilage resorption. Consequently, the facial foramen, situated posterior to the lateral commissure, is anteriorly open in this stage (Fig. 2A).

The auditory capsules are well developed. Dorsally, their roofs unite with each other to form a relatively wide cartilaginous plate representing the tectum synoticum (Fig. 1B). Anteriorly, each auditory capsule projects forward as a postorbital process (Fig. 1B), which passes insensibly into the taenia marginalis posterior. The lateral wall of each auditory capsule shows a narrow gap or vacuity due to resorption of cartilage (Fig. 1A). The floor of the auditory capsule on each side is fused with the corresponding parachordal plate by means of two commissures, *viz.* a wide anterior basicapsular commissure and a relatively narrow posterior one (Fig. 2A). Between the two commissures an oval basicapsular fenestra exists in front of which there is a small foramen, the glossopharyngeal foramen, through which the glossopharyngeal nerve emerges from the cranium. Farther posteriorly a foramen vagum, for the exit of the vagus nerve, is present behind the posterior basicapsular commissure (Fig. 2A).

No medial cartilaginous wall separates the brain cavity from the cavity of the auditory capsule, with the membranous labyrinth.

The external surface of the auditory capsule, on each side, shows prominences for accomodating parts of the membranous labyrinth.

Behind the auditory capsules, the parachordals bear laterally a pair of cartilaginous occipital plates. The occipital plate on each side fuses with the auditory capsule just behind the foramen vagum (Fig. 1B and 2A). However, the occipital plates are still separate from each other dorsally.

The cartilaginous skeleton of the splanchnocranium is well developed in this stage and consists of seven arches.

The first, or the mandibular arch, is represented by two cartilages: a palatoquadrate bar in the upper jaw and a Meckel's cartilage in the lower jaw (Fig. 1A).

The palatoquadrate is more expanded in an anteroposterior direction than in the 7 mm buccal stage (Ismail and Elshabka 1982), coinciding with general elongation of the neurocranium.

The pterygoid process of the palatoquadrate runs obliquely forward and upward. Anteriorly, it acquires a single articulation with the ethmoid plate, the ethmopalatine articulation. The quadrate part is a broad cartilaginous plate. Posteriorly, it exhibits a long metapterygoid process extending over the symplectic process of the hyosymplectic of the hyoid arch. Ventrally, the quadrate articulates with Meckel's cartilage (Fig. 1A).

Meckel's cartilage is a slightly curved rod running obliquely forward and upward from the point of its articulation with the quadrate. Anteriorly, it extends slightly beyond the ethmoid plate, but the two do not meet each other in the mid-line (Fig. 2A).

The hyoid arch on each side consists of four elements, known as the hyosymplectic, interhyal, ceratohyal and hypohyal cartilages (Fig. 2B). Of these, the first two represent the dorsolateral elements of the hyoid arch. The hyosymplectic is the longest part of the hyoid arch. It consists of a broad platelike part representing the hyomandibular element. Its dorsal margin, articulating with the ventrolateral part of the auditory capsule, is differentiated into two articular heads with a shallow concavity between (Fig. 1A, arrows). Ventrally, the hyomandibular is provided with a distinct opercular process with which the opercular bone articulates. It has a distinct small foramen, the hyomandibular foramen (Fig. 1A), for the passage of the hyomandibular branch of the facial nerve.

The symplectic process of the hyosymplectic is narrow and rodlike. It extends below the quadrate part of the palatoquadrate (Fig. 1A).

The interhyal is a small cartilaginous rod articulating dorsally with the posteroventral margin of the hyomandibular portion of the hyosymplectic and ventrally with the posterior part of the ceratohyal (Fig. 1A).

The ceratohyal is an elongate, platelike structure running obliquely forward toward the median line. Anteriorly, it articulates with an elongate, oval hypohyal. The two hypohyals meet in the midventral line (Fig. 2B).

The basihyal appears as an unpaired cartilaginous plate in the midventral line, broad anteriorly, narrow and slender posteriorly. Anteriorly, it overlaps dorsally the anteriormost portion of the anterior copula of the branchial arches (Fig. 2B).

All five pairs of branchial arches are present in this stage, elongated and enlarged as compared with the 7 mm buccal stage (Ismail and Elshabka 1982).

The first and second branchial arches consist of hypobranchial, ceratobranchial, epibranchial and infrapharyngobranchial elements (Fig. 2B). The second infrapharyngobranchial is provided with small vacuity due to cartilage resorption. Medial to the posterior end of the second infrapharyngobranchial is a small piece of cartilage probably representing the rostral part of the third infrapharyngobranchial.

The third branchial arch consists of hypobranchial, ceratobranchial and epibranchial. The hypobranchials of the first three arches articulate with a long median anterior copula with slight constrictions between the attachments of the hypobranchial elements (Fig. 2B).

The fourth branchial arch is represented by three elements: a ceratobranchial, an epibranchial and an infrapharyngobranchial; the hypobranchial cartilage, however, is absent as is the case in *Salmo* (Tchernavin 1938), *Mastacembelus armatus* (Bhargava 1958), *Tilapia nilotica* (Kasem 1959) and *Haplochromis elegans* (Ismail 1979). Medially, the fourth arch articulates with a small posterior copula, lying posterior to the anterior one (Fig. 2B).

The fifth branchial arch consists only of the ceratobranchials, each of which consists of two elements: an elongate, anterior cylinder and a small, posterior nodule. The anterior parts lie parallel to each other (Fig. 2B) and are connected medially by fine connective tissue fibres.

Stage II (12 mm total lenght, Fig. 4, 5 and 6)

At this stage, the chondrocranium is relatively longer and wider. Moreover, cartilage resorption is much more pronounced in comparison with the previous stage resulting in division of the neurocranium into anterior and posterior parts. (Fig. 4A,B and 5A). A similar condition has been observed in the 15 mm stage of *H. elegans* (Ismail 1979).

The anterior part of the trabecula communis is longer in comparison with the 9 mm stage. In transverse sections, it appears thicker and higher, with a dorsally pointed edge, to which the membranous interorbital septum is attached (Fig. 6C). The posterior part of the trabecula communis, represented by a median cartilaginous island, is now longer and massive than previously (Fig. 4A and 5A). Dorsally, it is partially ossified, forming a part of the basisphenoid bone.

The ethmoid plate is relatively broad, having grown farther laterally on both sides and thus providing a partial ventral support and protection for the olfactory organs (Fig. 5A, 6A and B). In transverse sections, the ethmoid plate is broad, massive and more convex dorsally against the ventral concave margin of the rostral cartilage (Fig. 6A). It has a ventral depression in which the prevomer and parasphenoid bones lodge.

The lamina orbitonasalis is more elongate in a dorsoventral direction (Fig. 4A). It extends anteriorly dorsal to the olfactory sac (Fig. 6B). In dorsal view, however, the lamina orbitonasalis, on each side, appears as a broad wing-like process projecting laterally from the ethmoid plate (Fig. 4B).

The internasal septum is longer and more massive than in the previous stage (Fig. 6B).

The rostral cartilage shows further enlargement and elongation compared with the previous stage (Fig. 1A and B and 4 A and B). This elongation coincides with the corresponding elongation of the ethmoid plate with which the rostral cartilage articulates.

The orbital cartilage, which forms the lateral wall of the orbitotemporal region of the neurocranium, is now discontinuous due to cartilage resorption. It consists mainly of the posterior part, representing the taenia marginalis posterior (Fig. 4A and B). The taenia marginalis anterior, however, is absorbed.

As a result of cartilage resorption, the epiphyseal cartilaginous bar has lost its connection with the orbital cartilages. It extends posteriorly to form an elongate process representing the taenia tecti medialis (Fig. 4B). All cartilages together form an independent triangular cartilaginous plate over the dorsomedial surface of the brain.

The auditory capsules are considerably longer and wider than in the previous stage. Dorsally, they are connected by a wide tectum synoticum extending farther in an anteroposterior direction than previously (Fig. 4B). The lateral wall of each auditory capsule has a pair of vacuities due to resorption of cartilage (Fig. 4A).

A pair of occipital plates is present posteriorly, continuous with the basal plate and not forming a tectum posterius dorsally (Fig. 4B).

In general, all elements of the splanchnocranium have considerably increased in length and thickness, compared with the previous stage.

The mandibular arch is essentially similar to that of the 9 mm stage. However, the palatoquadrate cartilage, previously represented by a continuous bar, consists now of two parts, due to the absorption of cartilage: a small anterior part and an elongate posterior one (Fig. 4A).

The hyomandibular portion of the hyosymplectic of the hyoid arch is now nearly twice as long as in the previous stage. The interhyal has grown in a dorsoventral direction (Fig. 4A).

The branchial arches do not show great differences from the previous stage, except that they are slightly elongated and enlarged.

The ceratobranchials of arches I-IV are expanded in an anteroposterior direction; their proximal ends are slightly thicker in comparison with the rest of the rods (Fig. 5B). The fifth ceratobranchials are now represented by two cartilaginous rods lying parallel to each other; the posterior parts, however, are completely resorbed (Fig. 5B).

The epibranchials I-IV are quite well developed and massive; the first epibranchial is the largest one (Fig. 5B).

The infrapharyngobranchials consist of four cartilaginous pieces of which the first is the smallest of the series (Fig. 5B).

The anterior and posterior copulae have grown further. The anteriormost part of the posterior copula lies dorsal to the caudal end of the anterior one (Fig. 5B).

Discussion

Like other Teleostei, *Sarotherodon galilaeus* undergoes an absorptive reduction of some of the chondrocranial cartilages during postembryonic development; a feature common among teleosts (Daget 1964).

In the present study, cartilage resorption is observed from the 9 mm stage onward, the cartilaginous neurocranial base losing its continuity at the level of the fenestra hypophysea. In the 12 mm stage, absorption is even more pronounced throughout the whole cartilaginous neurocranium, then divided into two independent compartments. The same was found in the cichlid fish *Haplochromis elegans* (Ismail 1979).

The absorption of cartilage at the level of the fenestra hypophysea starts earlier in ontogeny in *Sarotherodon galilaeus* than in other bony fishes such as *Clupea harengus* (Wells 1922), *Salmo salar* (De Beer 1937), *Ophicephalus* (Srinivasachar 1953) and *Salmo gairdneri* (Verraes 1974a), in which the discontinuity between the trabeculae and the parachordals occurs at later stages. This disparity may be correlated with different environmental conditions.

Of special interest in *Sarotherodon galilaeus* is the neurocranial pharyngobranchiad apophysis, with which the upper pharyngeal jaws articulate. This structure develops from the 9 mm stage onward and represents a characteristic feature of the cichlid neurocranium (Fryer and Iles 1972; Barel *et al.* 1976). A similar apophysis has been described in *H. elegans* (Ismail 1979).

In bony fishes, in general, the epiphyseal cartilage, together with the taenia tecti medialis, form the medial part of the cartilaginous neurocranial roof in the orbitotemporal region. In *Sarotherodon galilaeus*, the epiphyseal cartilage is well developed as a transverse cartilaginous bar connecting the orbital cartilages dorsally up to stage 9 mm total length. The taenia tecti medialis originates as a backward extension of the epiphyseal cartilage, as occurs also in some teleosts such as *Salmo* (De Beer 1937) and *Salmo gairdneri* (Verraes 1974 a). In *H. elegans*, however, the epiphyseal cartilage and the taenia tecti medialis develop separately, and unite with each other later, forming a single cartilaginous plate (Ismail 1979).

In *S. galilaeus*, the taenia tecti medialis extends posteriorly but does not reach the tectum synoticum of the auditory capsules, also as in *Salmo* (De Beer 1937), *Salmo gairdneri* (Verraes 1974 a), *Tylosurus* (Marathe and Suterwalas 1963) and *H. elegans* (Ismail 1979). In *Clupea harengus* (Wells 1922) and *Sebastes marinus* (Makintosh 1923), however, the taenia tecti medialis extends posteriorly and joins the roof of the auditory capsules.

In *S. galilaeus* and many teleosts such as *Salmo gairdneri* (Verraes 1973) and *H. elegans* (Ismail 1979), no medial cartilaginous wall separates the brain cavity of the neurocranium from the cavity of the auditory capsule in which the mambranous labyrinth is situated. In *Silonia*, however, medial cartilaginous walls have been found in the anterior and posterior regions of the auditory capsules, separating the cranial cavity from the cavity of the auditory capsule (Srinivasachar 1957).

In *S. galilaeus*, the pterygoid process of the palatoquadrate articulates with the cartilaginous neurocranium by means of an ethmopalatine articulation. In this respect, *S. galilaeus* resembles *H. elegans* (Ismail 1979). It differs, on the other hand, from *Salmo* (De Beer 1937) and *Salmo gairdneri* (Verraes 1973), in which the palatoquadrate on each side has in addition a rostropalatine articulation.

Acknowledgement

I am greatly indebted to Prof. Dr. Fawzi I. Amer (Department of Zoology, Faculty of Science, Ain shams University) for his critical review of the manuscript.

References

Barel, C.D., Witte, F., and Van Oijen, M.J.P. (1976) The shape of the skeletal elements in the head of a generalized *Haplochromis* species: *H. elegans* Trewavas, 1933 (Pisces, Cichlidae), *Neth. J. Zool.* **26** (2): 163-265.

Bhargava, H. (1958) The development of the chondrocranium of *Mastacembelus armatus* (Cuv. & Val.), *J.Morph.* **102:** 401-426.

Daget, J. (1964) Le crâne des Téléostéens, *Mém. Mus. natn. Hist. nat., Paris, Sér. A, Zool.* **31** (2): 163-341.

De Beer, G. (1937) *The development of the Vertebrate Skull*, Clarendon Press, Oxford, 552 p. + 143 pl.

Fryer, G. and **Iles, T.D.** (1972) *The Cichlid Fishes of the Great Lakes of Africa. Their Biology and Evolution*, Oliver & Boyd, Edinburgh, 641 p.

Ismail, M.H. (1979) *The Ontogeny of the Head Parts in* Haplochromis elegans *Trewavas. 1933 (Teleostei, Cichlidae).* Ph. D. thesis, Rijksuniversiteit Gent, Belgium, 228 p.

Ismail, M.H. and **Elshabka, H.A.** (1982) The postembryonic development of the chondrocranium of the Nile fish *Tilapia galilae,* Linnaeus. I. The buccal stages, *Bull. Fac. Sci., Zagazig Univ.* **4**: 291-323.

Kasem, I.A. (1959) The chondrocranium of *Tilapia nilotica* larva 7 mm, *Bull. zool. Soc. Egypt* **14:** 33-44.

Makintosh, N.A. (1923) The chondrocranium of the teleostean fish *Sebastes marinus, Proc. zool. Soc. Lond.* **2:** 501-513.

Marathe, V.B. and **Suterwalas, S.K.** (1963) The chondrocranium of *Tylosurus crocodilus* (Lesueur), *Proc. Indian Acad. Sci.* **57** (B) : 365-367.

Norman, J.R. (1926) The development of the chondrocranium of the Eel, *Anguilla vulgaris*, with observations on the comparative morphology and development of the chondrocranium in bony fishes, *Phil. Trans. R. Soc.* **214:** 369-464.

Srinivasachar, H. (1953) The development of the chondrocranium in *Ophicephalus, J. Linn. Soc., Zool.* **62:** 238-259.

—— (1957) Development of the skull in cat-fishes. I. Development of the chondrocranium in *Silonia, Pangasius* and *Ailia, Morph. J.* **22B** (6): 335-356.

Tchernavin, V. (1938) Notes in the chondrocranium and branchial skeleton of *Salmo*, *Proc. zool. Soc. Lond.* B: 347-364.

Trewavas, E. (1982) Tilapias: Taxonomy and Speciation, *In:* **Pullin, R.S.V.** and **Lowe-McConnell, R.H. (ed.)** The biology and culture of tilapias, *ICLARM Conference Proc. Manila, Philippines* **7:** 3-12.

Verraes, W. (1973) *Contribution to the Functional Morphology of the Constituting Elements of the Head of* Salmo gairdneri *Richardson, 1836 (Pisces, Teleostei) during Postembryonic Ontogeny with Special Attention to the Cranium and Muscles of the Head* (in Dutch). Ph.D. thesis, Rijksuniversiteit Gent, Belgium, 242 p.

—— (1974 a) Discussion on some functional morphological relations between some parts of the chondrocranium and the osteocranium in the skull base and the skull roof, and of some soft head parts during postembryonic development of *Salmo gairdneri* Richardson, 1836 (Teleostei: Salmonidae), *Forma et Functio* **7:** 281-292.

—— (1974 b) Notes on the graphical reconstruction technique, *Biol. Jaarb. Dodonea* **42:** 182-191.

Wells, F. (1922) On the morphology of the chondrocranium of the larval herring, *Clupea harengus*, *Proc. zool. Soc. Lond.* **2:** 1213-1229.

(Received 19/06/1983;
in revised form 28/11/1983)

List of Abbreviations

A. S. S	Anterior semicircular septum
A. COP	Anterior copula
A. BC. C	Anterior basicapsular commissure
AU. CAP	Auditory capsule
B.F	Basicapsular fenestra
B. H	Basihyal
BR	Brain
C. B	Ceratobranchial
C. H	Ceratohyal
CAR. RES	Cartilage resorption
COM. S	Commissura sphenoseptalis
COR. PR	Coronoid process of Meckel's cartilage
E. B	Epibranchial
E. PL	Ethmoid plate
EP. C	Epiphyseal cartilaginous bar
EP. COM	Epichordal commissure
EY	Eye
EY. L	Eye lens
F. F	Facial foramen
F. H	Fenestra hypophysea
F. PO	Fontanella postpinealis
F. PR	Fontanella praepinealis
FOR. G	Foramen glossopharyngeum
FOR. V	Foramen vagum
FR	Frontal bone
H. B	Hypobranchial
H. H	Hypohyal
H. F	Hyomandibular foramen
H. S	Hyosymplectic
I. H	Interhyal
I. O. S	Interorbital septum
I. Ph. B	Infrapharyngobranchial
IN.S	Internasal septum
INT. P. F	Interparachordal fenestra
L. L	Lower lip
LAB	Membranous labyrinth
LAM. OR	Lamina orbitonasalis
M. C	Meckel's cartilage
MET. BR	Metapterygoid process of the palatoquadrate
N	Notochord
N. PH. AP	Neurocranial pharyngobranchiad apophysis
OC. P	Occipital plate
OLF. O	Olfactory organ
OLF. S	Olfactory sac
OPE	Opercular bone
P	Palatoquadrate
P. S. S	Posterior semicircular septum
P. BC. C	Posterior basicapsular commissure
P. COP	Posterior copula
P. PR	Postorbital process
PAR. PL	Parachordal plate
PR. BR	Prootic bridge
PT. PR	Pterygoid process of the palatoquadrate
Q	Pars quadrata of the palatoquadrate
R	Rostrum
R. C	Rostral cartilage
RA. BR	Retroarticular process of Meckel's cartilage
S. COM	Sphenoseptal commissure
S. OR. C	Supraorbital canal
SY. PR	Symplectic process of the hyosymplectic
T	Trabecula crani
T. COM	Trabecula communis
T. MAR. A	Taenia marginalis anterior
T. MAR. P	Taenia marginalis posterior
T. SYN	Tectum synoticum
T. T. M	Taenia tecti medialis
U. L	Upper lip

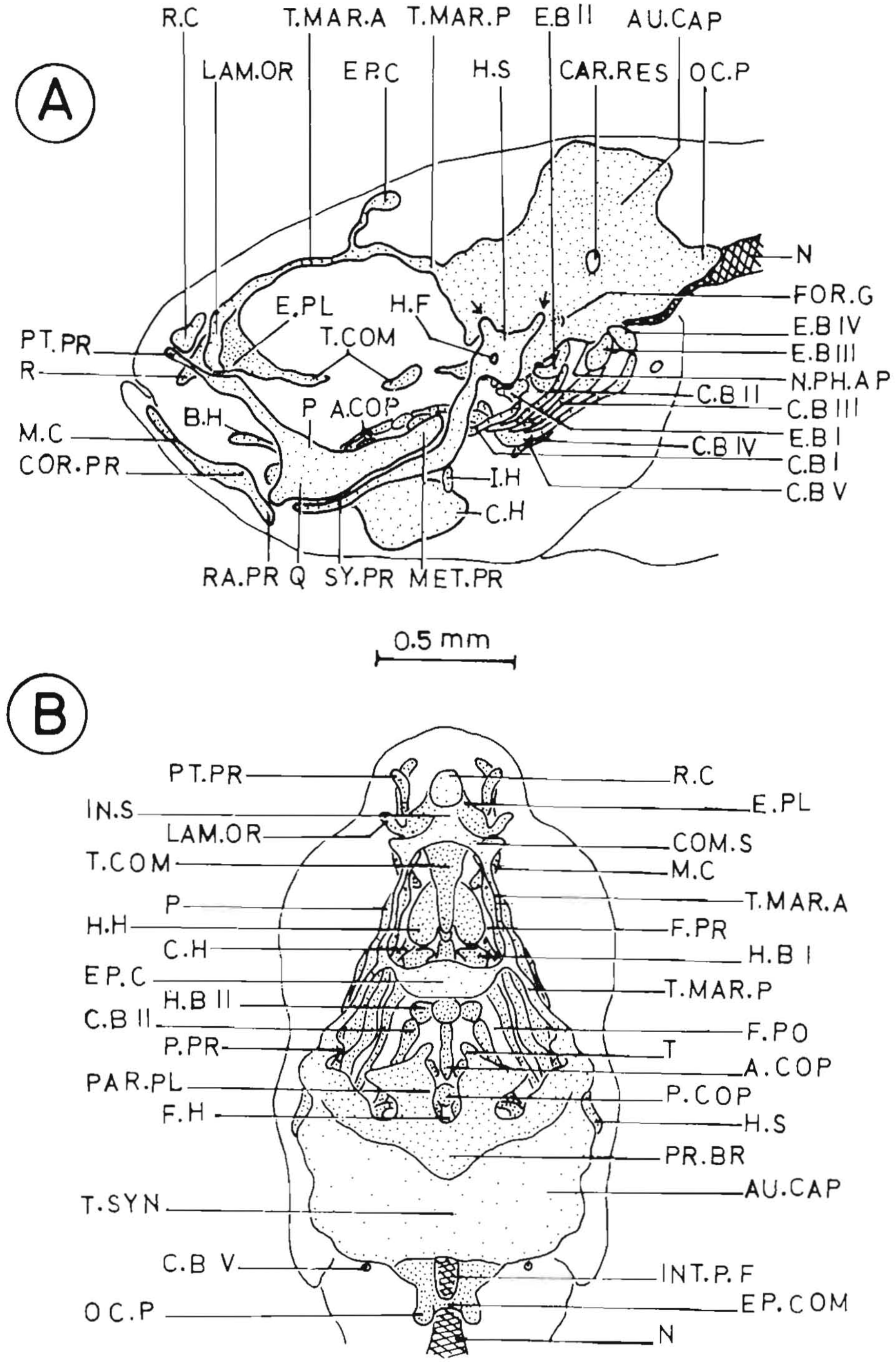

Fig. 1. Graphical reconstructions of the chondrocranium, notochord and head contour of the 9 mm stage of *S. galilaeus*. **A**, lateral view; **B**, dorsal view.

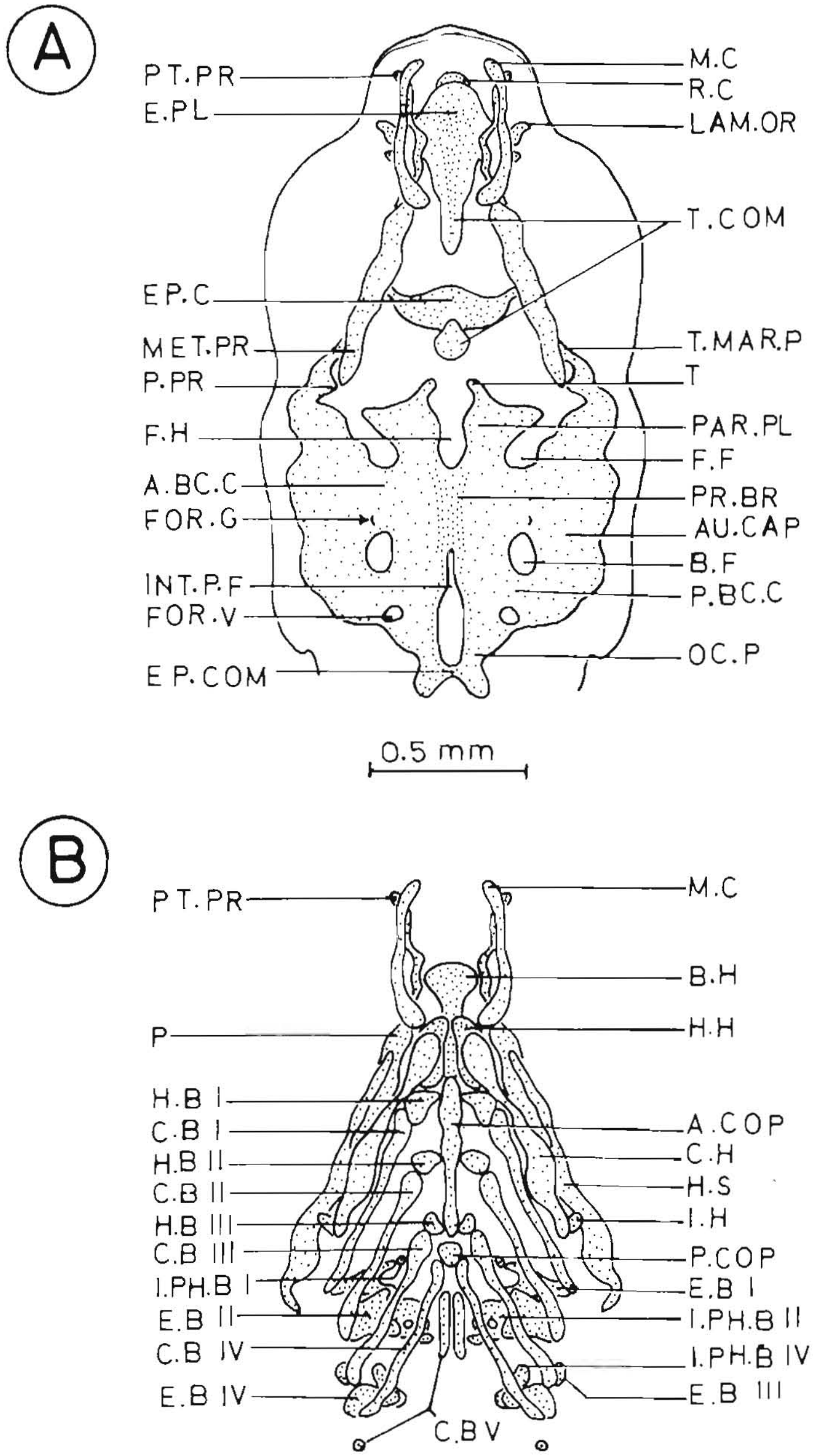

Fig. 2. **A**, graphical reconstruction (ventral view) of the cartilaginous neurocranium, mandibular arch and head contour of the 9 mm stage of *S. galilaeus*. **B**, graphical reconstruction (ventral view) of the splanchnocranium of the 9 mm stage of *S. galilaeus*.

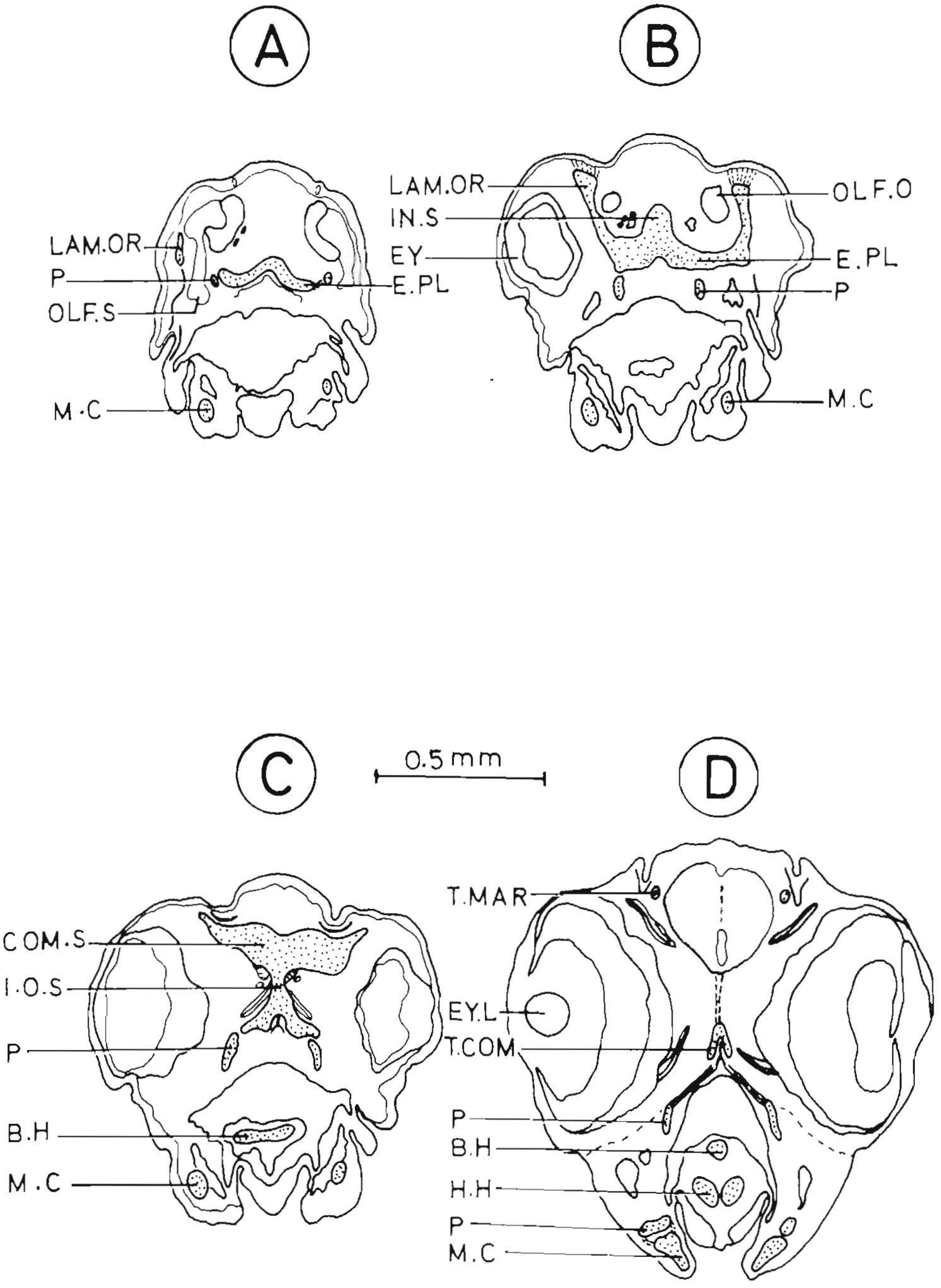

Fig. 3. Cross sections through the head of the 9 mm stage of *S. galilaeus*. **A**, **B**, ethmoid region; **C**, **D**, orbital region.

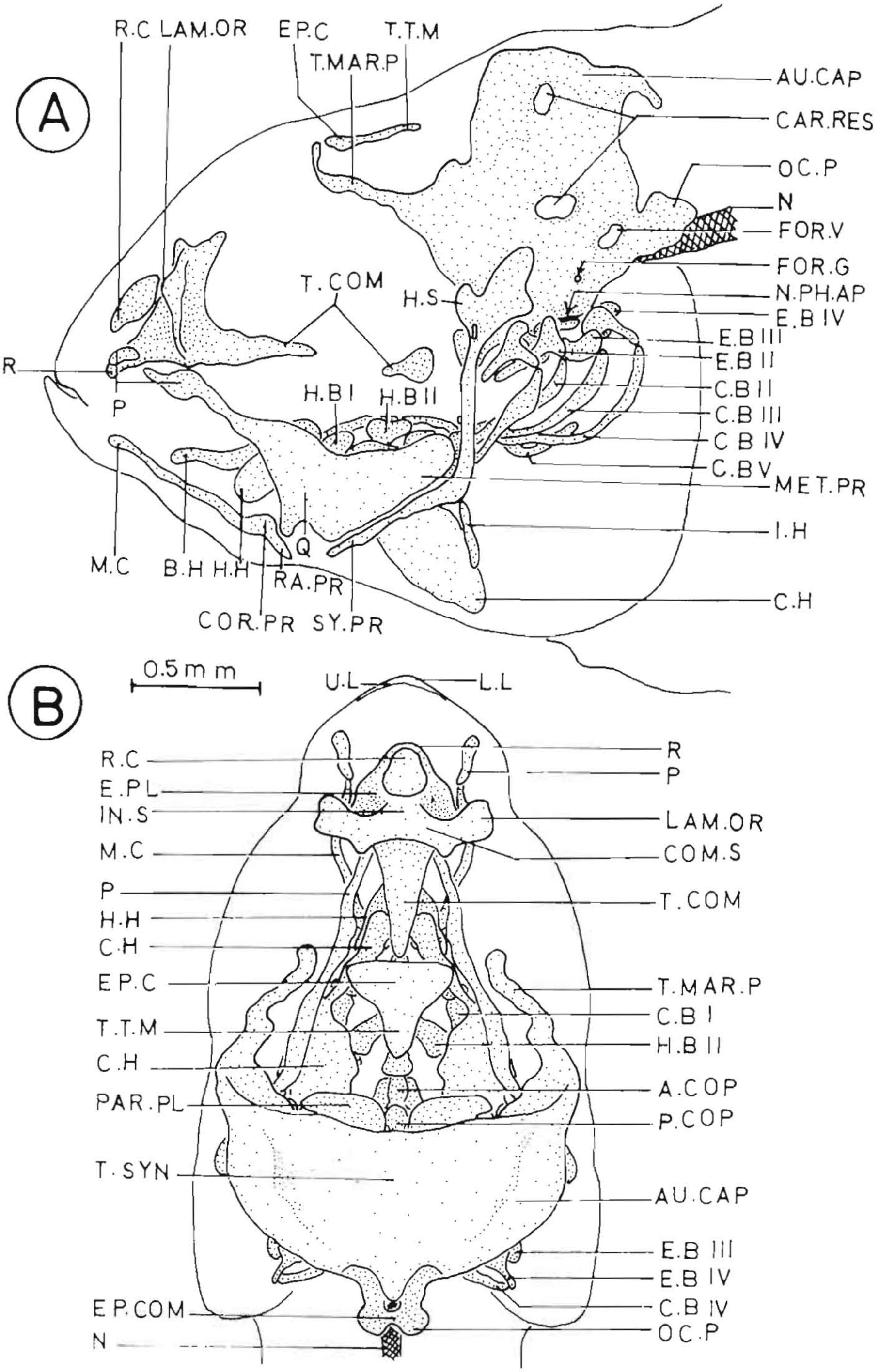

Fig. 4. Graphical reconstructions of the chondrocranium, notochord and head contour of the 12 mm stage of *S. galilaeus*. **A**, lateral view; **B**, dorsal view.

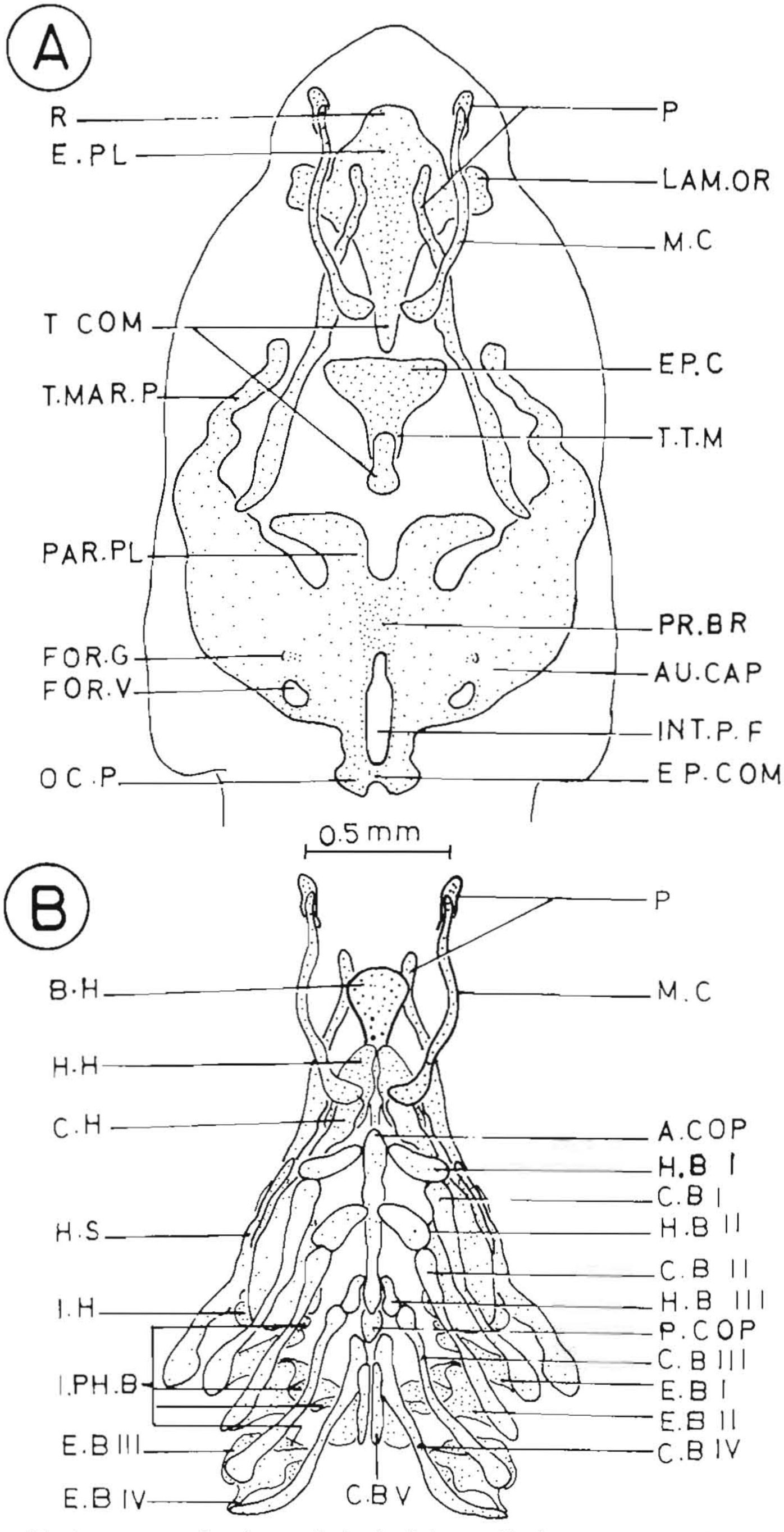

Fig. 5. **A**, graphical reconstruction (ventral view) of the cartilaginous neurocranium, mandibular arch and head contour of the 12 mm stage of *S. galilaeus*. **B**, graphical reconstruction (ventral view) of the splanchnocranium of the 12 mm stage of *S. galilaeus*.

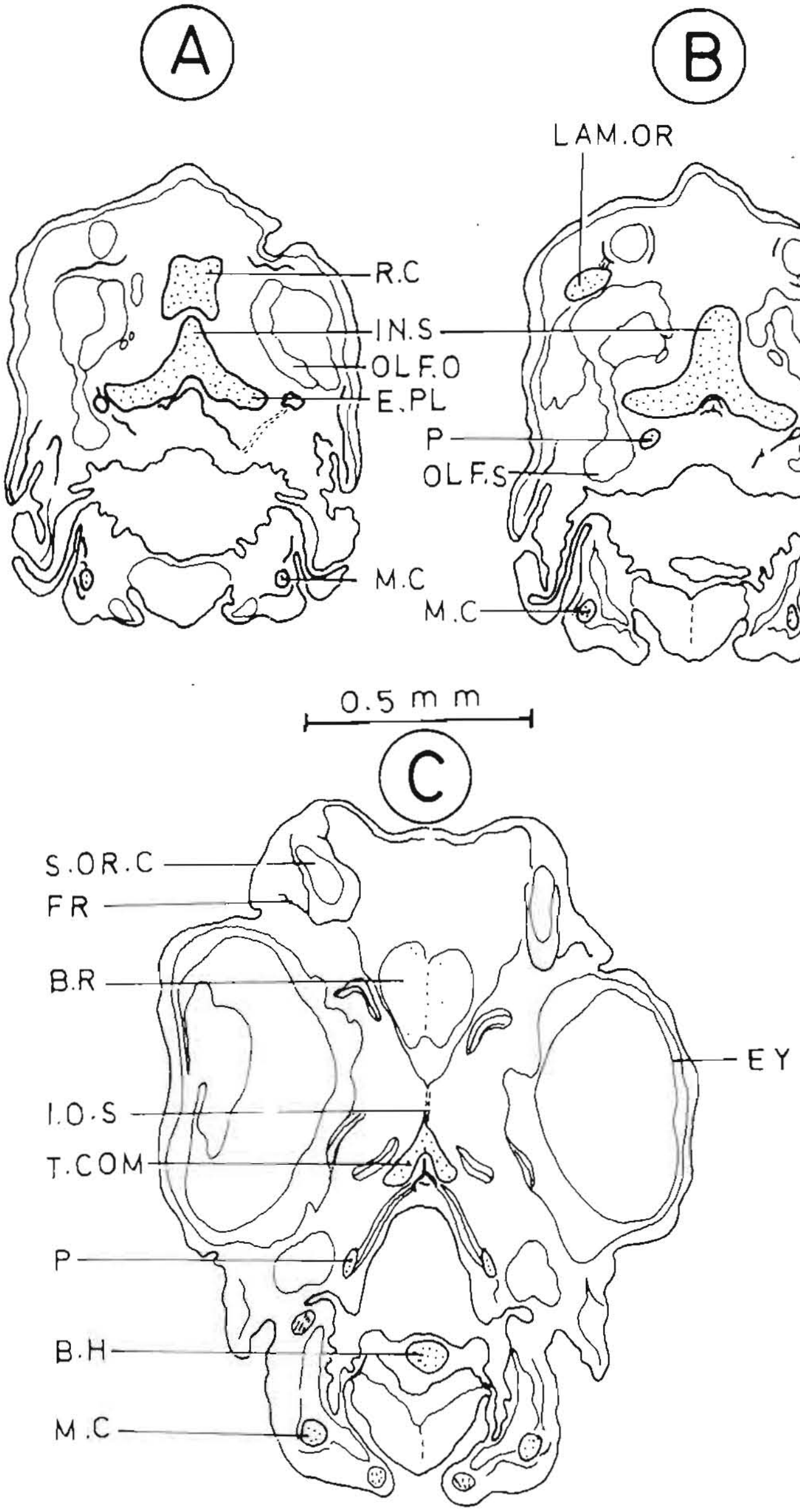

Fig. 6. Cross sections through the head of the 12 mm stage of *S. galilaeus*. **A**, **B**. ethmoid region; **C**, orbital region.

التكوين مابعد الجنينى للجمجمه الغضروفيه فى سمك البلطى الجاليلى فيما بعد الأطوار الفميه

ممتاز هاشم اسماعيل

قسم علم الحيوان - كلية العلوم - جامعة الزقازيق الزقازيق - مصر

يتضمن هذا البحث دراسه تكوين الجمجمه الغضروفيه فى السمك البلطى الجاليلى وهو أحد أسماك النيل العظمية فى المرحلة ما بعد الجنينية - وقد تضمنت الدراسة وصف الجمجمة الغضروفية العصبية والحشوية فى طورين من أطوار مابعد المرحلة الفمية وهى المرحله التى تغادر فيها اليرقات التجويف الفمى للأبوين وتصبح حرة المعيشة و طول كل منهما ٩ مم ، ١٢ مم بعمر ١١ ، ١٤ يوما بعد الإخصاب على التوالى .

وقد لوحظ وجود امتصاص غضروفى فى الجمجمة العصبية فى مرحلة ٩ مم طول عند مستوى الكوة النخامية وزاد معدل هذا الامتصاص فى مرحله ١٢ مم طول. وجدير بالذكر أن عملية الامتصاص الغضروفى فى هذا النوع من الأسماك تبدأ فى مرحله مبكرة وذلك بالمقارنة بالأنواع الأخرى من الأسماك العظمية وقد يعزى ذلك إلى اختلاف الظروف البيئية المحيطة. الجمجمة مزوده بنتؤ بلعومى يتكون فى مرحلة ٩ مم طول كبر وز بطنى من الجزء القاعدى للجمجمة فى المنطقة الأذنية. ويعتبر هذا النتؤ صفة مميزة للأسماك

المشطية - كما لوحظ أيضا وجود غضروفى بوزى وسطى يقع ظهريا بالنسبه للصفيحة الغضروفية المصفوية للجمجمة العصبية .

وتتكون الجمجمة الحشوية من ثلاث مجموعات من الأقواس الحشوية هى القوس الفكى والقوس اللامى ثم الأقواس الخيشومية وعددها خمسة أزواج .

ويتركب القوس الفكى على كل جانب من جزء علوى هو العارضة الحنكية المربعية وجزء سفلى هو غضروف ميكل - ويتمفصل الجزء العلوى مع الجزء المصفوى للجمجمة العصبيه من جهة ومع غضروف ميكل من جهة أخرى .

أما القوس اللامى فهو يتركب من خمس قطع هى اللامى القاعدى واللامى السفلى واللامى القرنى والبين لامى ثم اللامى الفكى . ويتمفصل الأخير على الجزء الأذنى للجمجمة العصبية .

والأقواس الخيشومية ممثلة بخمسة أزواج يتكون الثلاثة الأول منها على كل جانب من أربع قطع هى الخيشومى السفلى والقرنى والعلوى والبلعومى - والجزء الخيشومى السفلى غائب فى الزوج الرابع من الأقواس الخيشومية - أما الزوج الخامس فيتكون فقط من الخيشومى القرنى وتتمفصل الأقواس الخيشومية من الناحية البطنية بقطعتين من الغضاريف الرابطة إحدهما أمامية طويلة نسبيا والأخرى خلفية قصيرة .